

PATIENT

Nike Chuck

SPECIES

Canine

BREED

Portugese Water Dog

SEX

Spayed Female

AGE

13 years

WEIGHT

42.4 lbs

INTERPRETED BY

Andrea Nicastro, DVM,
Diplomate ACVIM (Small
Animal Internal Medicine)

IMAGING PERFORMED BY

Loetitia Saint-Jacques,
RVT LVT

HOSPITAL NAME

South Reno VH

REFERRING VET

Dr Schmitt

INVOICE

11614

DATE

9.9.22

PRESENTING CLINICAL SIGNS

History: No sedation- No medications- history of ataxia and dx vestibular- Owner moved to Reno,NV from Chicago on July 1. Patient seems to be reluctant to go very far on walks. AUS to r/o neoplasia- Abnormal PE/Chem/CBC/UA Results: Grade 4/6 left-sided systolic base heart murmur and lungs auscult and femoral pulses within normal limits. Severe dental calculus. HR 131-

ULTRASONOGRAPHIC EXAMINATION OF THE ABDOMEN

Urinary System

The **urinary bladder** wall is normal in thickness and the mucosal surface is smooth. The bladder lumen is moderately distended with anechoic urine. No masses, inflammatory changes or calculi are observed. Ureteral papillae and visualized portion of the proximal urethra, visible to a depth of 2 cm, are normal.

The **left kidney** is normal size (6.15 cm in length); normal shape and architecture with smooth peripheral margins. There is a normal 1:3 cortex to medulla ratio with minimal loss of corticomedullary distinction. There is no evidence of pyelectasia, nephroliths, infarcts or hydroureter.

The **right kidney** is normal size (6.70 cm in length); normal shape and architecture with smooth peripheral margins. There is a normal 1:3 cortex to medulla ratio with minimal loss of corticomedullary distinction. There is no evidence of pyelectasia, nephroliths, infarcts or hydroureter.

Adrenal Glands

The **left adrenal gland** is normal size (0.40 cm at cranial pole) (0.40 cm at caudal pole); normal shape; homogenous parenchyma. The glandular echogenicity and detail are unremarkable. Capsule, cortex, and medullary definition are normal. The phrenicoabdominal vein and surrounding vasculature are normal.

The **right adrenal gland** is normal size (1.37 cm at cranial pole) (0.55 cm at caudal pole) (2.97 cm in length); normal shape; homogenous parenchyma. The glandular echogenicity and detail are unremarkable. Capsule, cortex, and medullary definition are normal. The phrenicoabdominal vein and surrounding vasculature are normal.

Spleen

The **spleen** is normal in size (1.85 cm in width at the level of the hilus) with a normal capsular contour. There is appropriate echogenicity and echotexture. No focal lesions are observed. Splenic vasculature is normal.

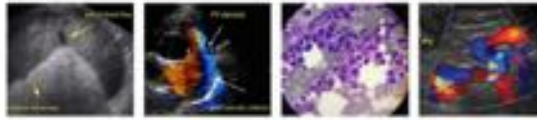
Liver

The **liver** is subjectively normal in size with normal curvilinear peripheral contours. The parenchyma is hypoechoic relative to the spleen. An approximately 4.00 cm irregular/ill-defined hyperechoic to slightly heterogenous nodule/mass is observed on the right side. The remaining parenchyma is homogenous. Hepatic vasculature and intrahepatic biliary tracts are of normal volume with no evidence of congestion. observed.

The **gall bladder** lumen is moderately distended. The wall is thin and smooth. Luminal contents are mostly anechoic. The cystic and common bile ducts are normal/not seen.

Gastrointestinal

The **gastric lumen** is not distended. The gastric wall is normal in thickness with a normal layering pattern. The pyloric outflow tract is patent. The small intestinal lumen is segmentally dilated with chyme. The small intestinal wall is normal in thickness with retention of the normal layering pattern.



PATIENT

Nike Chuck There is evidence of mucosal striations in some segments. Discreet masses are not identified. The colonic wall is normal. There is no evidence of an obstructive pattern.

SPECIES

Pancreas

Canine

The region of the **pancreas** is isoechoic relative to surrounding omental fat. No obvious parenchymal abnormalities are observed. There is no evidence of regional inflammation or effusion.

BREED

Free Abdomen

Portugese Water Dog

The **peritoneal cavity** is normal. There is no evidence of inflammation or effusion. The abdominal **lymph nodes** are normal/not visible.

ULTRASONOGRAPHIC FINDINGS

SEX

Primary Findings

Spayed Female

- The mucosal linear striations seen in the small intestine are suggestive of lymphangiectasia. However, correlation with the patient's clinical signs is recommended.

AGE

13 years

- The right hepatic nodule/mass could be consistent with a benign process (i.e., regenerative nodular hyperplasia). Alternatively, neoplasia (i.e., adenoma, adenocarcinoma) may be present. This lesion is not likely to be associated with the patient's neurologic disease.

WEIGHT

42.4 lbs

INTERPRETATION OF THE FINDINGS & FURTHER RECOMMENDATIONS

- Baseline lab work, including a CBC, Chemistry panel, urinalysis and T4 is recommended, if not already performed.
- Three-view thoracic radiographs are recommended to assess cardiopulmonary status.
- Consider a consultation with a board-certified oncologist to further evaluate the patient's neurologic signs.

INTERPRETED BY

Andrea Nicastro, DVM,
Diplomate ACVIM (Small
Animal Internal Medicine)

IMAGING PERFORMED BY

Loetitia Saint-Jacques,
RVT LVT

HOSPITAL NAME

South Reno VH

REFERRING VET

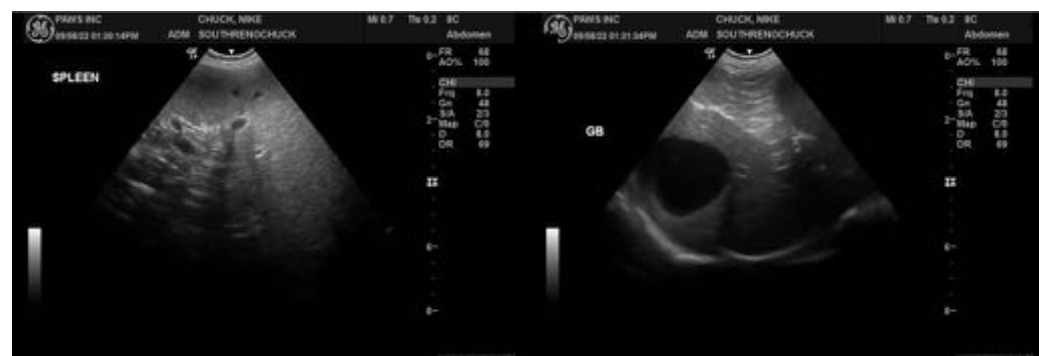
Dr Schmitt

INVOICE

11614

DATE

9.9.22





PATIENT

Nike Chuck

SPECIES

Canine

BREED

Portugese Water Dog

SEX

Spayed Female

AGE

13 years

WEIGHT

42.4 lbs

INTERPRETED BY

Andrea Nicastro, DVM,
Diplomate ACVIM (Small
Animal Internal Medicine)

**IMAGING
PERFORMED BY**

Loetitia Saint-Jacques,
RVT LVT

HOSPITAL NAME

South Reno VH

REFERRING VET

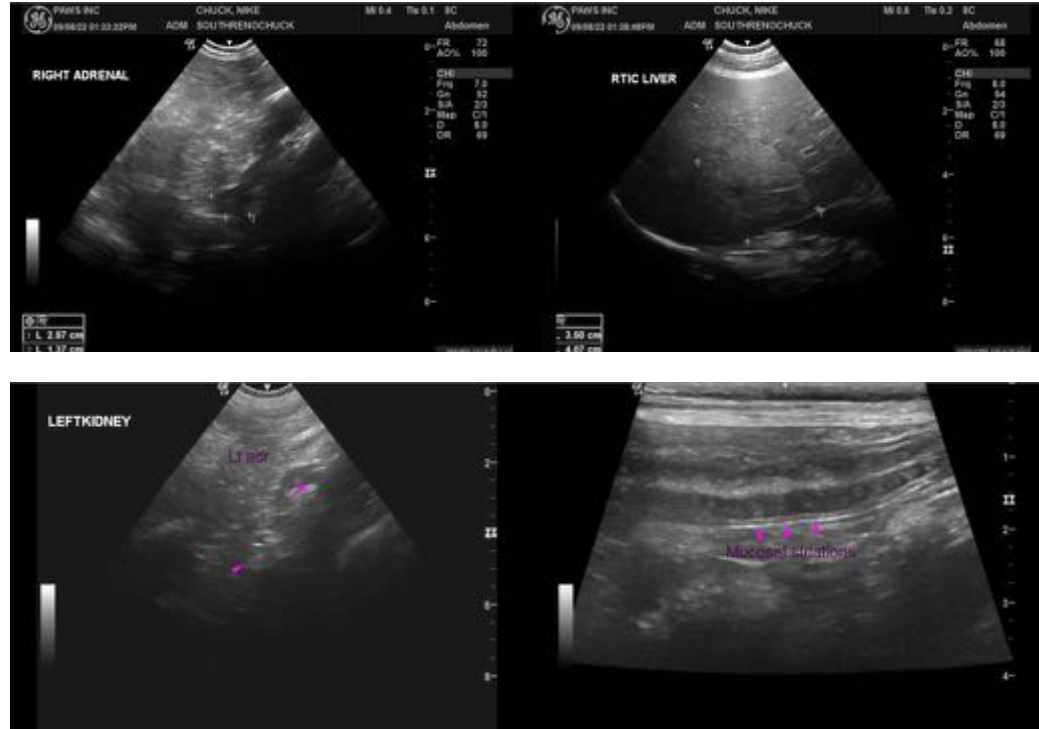
Dr Schmitt

INVOICE

11614

DATE

9.9.22



The information and recommendations provided are based on the images presented by the referring veterinarian/sonographer. No evaluation can be communicated regarding pathology that was not visible in the image/video clips provided.

Thank you for this referral. If the clinical or image interpretation does not parallel your findings or if I can be of any further assistance, please contact me.

Andrea Nicastro, MPH, DVM, Diplomate DACVIM (Small Animal Internal Medicine)
info@SonoPath.com